

# Unit



## Common Eye Problems

### INTRODUCTION

The eye care staff performs eye examination and carefully test every aspect concerned with the eyes.

In this unit, you will learn about common eye problems affecting the various anatomical structures of the eye, for example conjunctiva, cornea, retina, intraocular lens, etc. The unit will also cover the diseases caused by pathogens, for example by bacteria, viruses, etc. Eye infection can spread from person to person, by contact of pathogens through eyewear, eye cover and objects touched by an infected patient.



171163CH03

#### Biological agent

Any living organism (for example, virus or bacteria) that affects the body, a part of the body, or any of its functions are called biological agents. Their effects may be beneficial or harmful.

The students will also learn about the various diseases affecting different anatomical structure of the eyes, like conjunctival hyperaemia, conjunctival chemosis, sub-conjunctival haemorrhage xerosis and inflammatory conditions of conjunctiva. Further, they will also learn about the common diseases of cornea, such as corneal abrasion or keratitis. The students will be taught about age-related macular degeneration, glaucoma and cataract.

### Did you know?

Damage to or malfunction of any part of the visual system can lead to significant loss of visual functioning. For example, if any of the structures involved in the transmission of light, like the cornea, pupil, eye lens, aqueous humour and vitreous humour, or those responsible for conversion of light to electrical impulse, like the retina or even the optic nerve that transmits these impulses to the brain, is damaged, it will result in visual impairment. You might have experienced that you are not able to see objects clearly for some time when you enter from a brightly lit to a dimly lit room. The pupil of the eye acts like a variable aperture whose size can be varied with the help of the iris. When the light is very bright, the iris contracts the pupil to allow less light to enter the eye. However, in dim light the iris expands the pupil to allow more light to enter the eye. Thus, the pupil opens completely through the relaxation of the iris.

After reading this Unit, the students will know about the types of refractive errors, many symptoms related to eye problems, such as watery eyes, redness, headache, coloured haloes, and photophobia, etc.

#### Bifocal

Lens with one segment for near vision and one segment for far vision are called Bifocal. The term 'bifocal' can apply to both eyeglass and contact lenses.

The knowledge about eye injuries by any source should be taken care of at the earliest so that further complication can be avoided. The injuries can be mechanical, physical or chemical-oriented. The proverb 'prevention is better than cure' is of utmost importance and to be valued. If at all injury takes place, the vision technician needs to know primary care measures.

## SESSION 1: COMMON EYE PROBLEMS AND INFECTIONS

In this session, you will learn about the common eye problems, which include red eyes, itching, injuries, conjunctivitis, corneal diseases, etc.

An eye disease, induced by pathogens, for example bacteria, viruses and different other microorganisms, causes an eye infection. A large number of the viruses, bacteria, parasite, and other organisms that can attack the human body are capable of affecting the inner part of the eye. Eye infections can range from the normal conjunctivitis to other rare allergies. Eye infections can fluctuate in the level of seriousness, yet many times, they are not difficult to cure.

Eye infections are typically transferable from one person to another. An eye infection may occur due to immediate contact by touching eyewear or eye covers of an infected person. Infections could be brought on through infected eyewear, eye surgery, trauma to the eye or deficiency of vitamins, etc. However, infections can be more regular around the individuals who wear contact lenses, to a great extent due to infections in the contact lens. The symptoms for different infections



contrast. The most commonly-known type of infection is bacterial conjunctivitis which results in red, swollen and itchy eyes. There is regular release of fluid and a steady disturbance in bacterial conjunctivitis.

## **Conjunctiva and its diseases**

It is a thin membrane that covers the inner surface of the eyelid and the white part of the eyeball (the sclera). Inflammation of the conjunctiva is called conjunctivitis. It makes the white of the eye look red, which is also called conjunctival hyperemia.

### **Conjunctival chemosis**

It is the swelling of the conjunctiva. Effective treatment includes cold compresses, chilled artificial tears and steroid eye drops.

### **Sub-conjunctival haemorrhage**

It is the bleeding underneath the conjunctiva. The conjunctiva contains many small, fragile blood vessels that are easily ruptured or broken. When this happens, blood leaks into the space between the conjunctiva and sclera.

### **Conjunctival xerosis**

Dryness of the eye surface caused by deficiency of tears or conjunctival secretions is known as conjunctival xerosis. It may be associated with vitamin A deficiency, trauma, or any condition in which the eyelids do not close completely.

## **Inflammatory conditions**

An inflammatory condition is known as conjunctivitis, also called 'pinkeye'. These may include:

### **Infective viral and bacterial conjunctivitis**

Viral conjunctivitis and bacterial conjunctivitis may affect one or both the eyes. Bacterial conjunctivitis often produces a thicker, yellow-green discharge. Both types can be associated with cold or the symptoms of a respiratory infection, such as a sore throat. Both viral and bacterial types are very contagious. They are spread

through direct or indirect contact with the eye secretions of an infected person. Adults and children can both develop these types of pinkeye. Bacterial conjunctivitis is more common in children than in adults.

### Allergic conjunctivitis

It affects both the eyes and is a response to an allergy-causing substance, such as pollen dust or cosmetics. The body's release of histamine can produce a number of allergy signs and symptoms, including red or pink eyes. If you have allergic conjunctivitis, you may experience intense itching, tearing and inflammation of the eyes, as well as sneezing and watery nasal discharge.

### Chemical or irritational conjunctivitis

It is not contagious and is caused by exposure to irritants including chlorine from swimming pools, contact lens solutions, cosmetics, foreign objects, injury to the eye, intense light (i.e., snow blindness) and smoke.

### Cornea: Its disorders and diseases

The cornea is the transparent part of the eye that covers the front portion of the eye. It covers the pupil, iris and anterior chamber of eye. The cornea's main function is to refract the light rays when they enter the eye. The cornea is responsible to focus most of the light that enters the eye.

### Diseases of cornea

Even though the cornea appears clear in such condition, the patient's vision can still be very blurry (Fig.3.1).

### Corneal abrasion

A scratch on the surface of the cornea. It may occur by dust, contact lenses, or any other objects.

### Glaucoma

It refers to a group of eye diseases wherein the optic nerve gets progressively destroyed (Fig.3.2). This is often due to an increase of pressure within the eye,

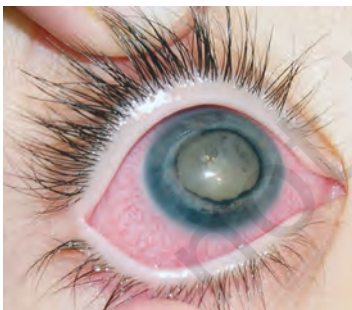
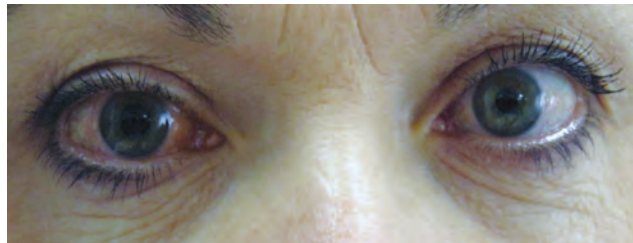
Fig. 3.1: Corneal Disease

resulting in gradual vision loss and, eventually blindness. (IOP). Normal intra ocular pressure is 14.6–22.04 mm of mercury, it is measured by an instrument named schiottz tonometer.

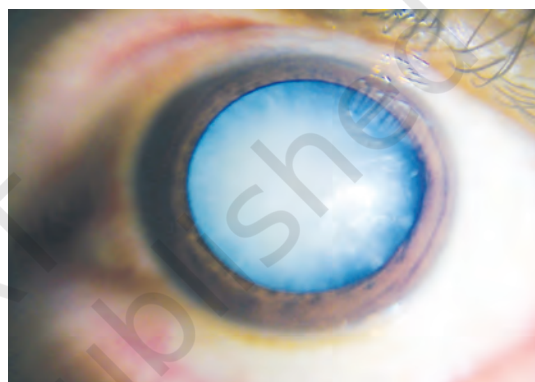
Another instrument used to measure IOP is called the applanation tonometer. It is generally brought about by anomalous high pressure inside the eyeball. There are restrictions in the field of vision as a result of the damage to the optic nerve.



*Fig. 3.2: Glaucoma*

## **Cataract**

It is the clouding of the eye's natural lens, which lies behind the iris and the pupil (Fig. 3.3). Cataracts, most commonly cause diminishing of vision in people over 40 years of age, and is the principal cause of blindness. A cataract starts out small and at first, has little effect on the vision. One may notice that the vision has blurred a little, like looking through a cloudy piece of glass or viewing an impressionist painting.



*Fig. 3.3: Cataract*

## **Practical Exercise**

### **Activity 1**

Prepare a chart of the common eye problems. Paste pictures or drawings and mention the common symptoms associated with the eye problems.

#### **Materials required**

1. Chart paper
2. Scissor
3. Adhesive
4. Sketch pens
5. Eraser
6. Scale and
7. Pictures of common eye conditions



**Check Your Progress****A. Fill in the blanks**

1. An eye disease induced by \_\_\_\_\_, for example, bacteria, viruses and different other microorganisms, causes an eye infection.
2. Eye infections can range from the normal conjunctivitis to rare \_\_\_\_\_.
3. The conjunctiva is a thin membrane that covers the inner surface of the \_\_\_\_\_ and the white part of the eyeball (the sclera).
4. Inflammation of the conjunctiva is called \_\_\_\_\_. It makes the white of the eye look red.

**B. Short answer questions**

1. What is conjunctival chemosis?
2. Which disease is caused by Anomalous High Pressure inside the eyeball? Explain how?
3. What is cataract?

**SESSION 2: SYMPTOMS OF COMMON EYE PROBLEMS**

In this session, you will learn about the common eye problems, which may include defects of vision, blurry vision, etc.

**Common symptoms**

Some of the common symptoms of eye problems include the following:

**Watering of eyes**

This could be due to inflammation of cornea or conjunctiva and other conditions, such as blocked lacrimal passages and the presence of a foreign body.

**Redness of the eye**

This can be due to the presence of a foreign body, conjunctivitis, keratitis, anterior uveitis, angle closure, glaucoma, etc.



## Swelling

Incorrect error of refraction can cause headache. Other causes could be a migraine, sinusitis or tension.

## Coloured halos around bulbs

This is suggestive of angle closure glaucoma, corneal edema and acute conjunctivitis with mucus crusts.

## Diplopia (double vision) or multiple images

This may be due to a squint, corneal edema, cataract, astigmatism and subluxated lens.

## Photophobia

This means the fear of light which is caused due to corneal abrasions, corneal ulcers, anterior uveitis, and acute closure glaucoma. It is due to ciliary spasm activated by light.

## Itching

This is an indicator of some kind of allergy or conjunctivitis or dry eyes.

## Defects of vision

Sometimes the vision is blurred due to an inability of the rays of light to focus clearly on the retina. This is called visual defect and it occurs due to the refractive error of the eye.

The three major errors of refraction are:

- Myopia (nearsightedness)
- Hyperopia (farsightedness)
- Astigmatism

## Myopia

It is a condition when a person can see nearby objects clearly but cannot see distant objects. It usually develops in childhood or young age. In

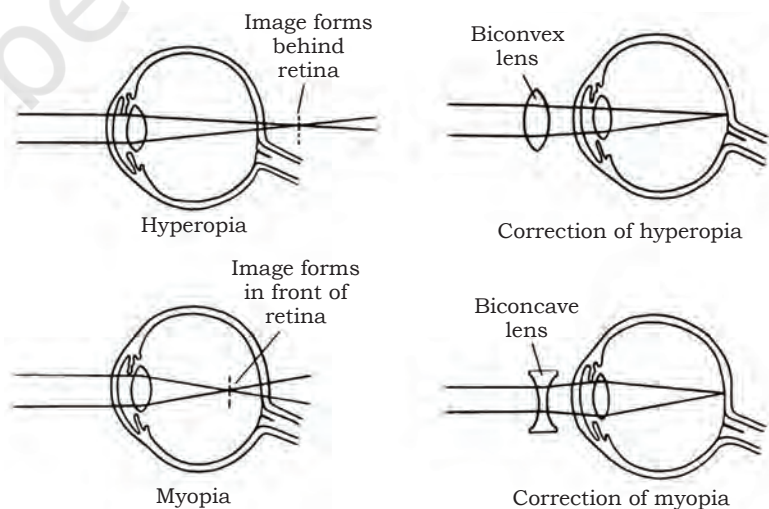


Fig. 3.4: Hyperopia and Myopia

this condition, the light from an object is focussed in front of the retina. The condition is due to elongation of the eyeball or change in curvature of the eye lens.

## Symptoms

The main symptom of myopia is blurred vision and an inability to see distant objects. Other symptoms of the visual defect are headache, watery eyes, itching and dryness in the eyes. Children who suffer from myopia find it difficult to see letters distinctly written on the blackboard when sitting on the back benches of the classroom.

## Types of myopia

There are generally two types of myopia.

**1. Simple myopia:** The power in simple myopia is usually less than 6 dioptre. Dioptre is the unit of power of a lens.

**2. Pathological myopia:** In this type of myopia, the refractive defect of the eye is very high. It is progressive and generally present from early childhood. The power is usually more than 6 dioptre.

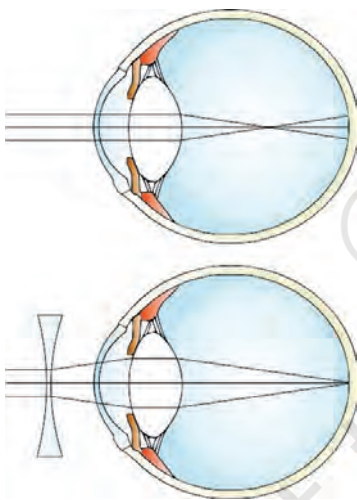


Fig. 3.5: Myopia Treatment

## Treatment

Myopia can be corrected by using concave lens of suitable power (Fig. 3.5). The concave lens can help to form an image on the retina.

## Hypermetropia

Hypermetropia or Hyperopia or far-sightedness is a condition in which the person can see distant objects clearly but is unable to see the nearby objects distinctly. This condition is caused when light from an object is focussed at a point behind the retina. The size of the eyeball in hypermetropia is smaller than normal.

## Symptoms

A person with hyperopia cannot see nearby objects distinctly. The other symptoms are headache, strain in the eyes after prolonged work involving looking at nearby



objects, such as desk job, sewing, knitting, etc. Hyperopia can be detected at any age.

### Treatment

Hyperopia is corrected by the use of a convex lens of suitable power.

### Astigmatism

A person suffering from astigmatism has blurred, distorted or fuzzy vision, as the light rays are focussed on two or more points on the retina (Fig. 3.6).

### Symptoms

A person with astigmatism complains of headache or eye strain and blurred vision.

### Treatment

Astigmatism is corrected by the use of a cylindrical lens in the spectacles.

### Presbyopia

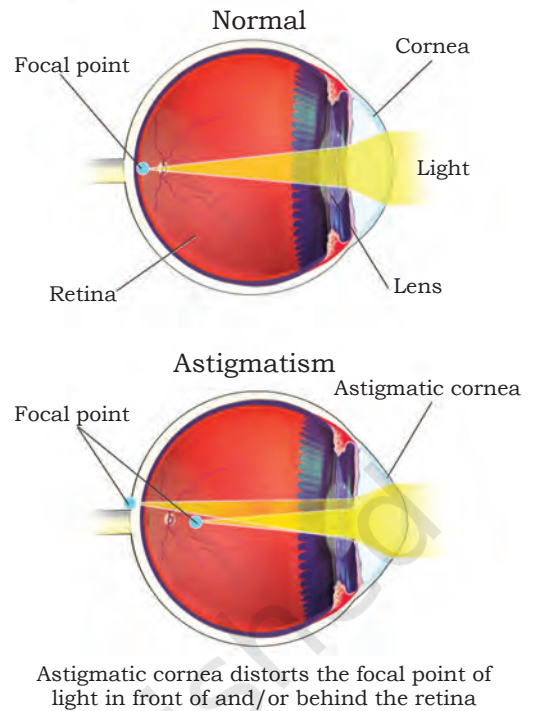
The power of the eye to see nearby objects decreases with ageing. They find it difficult to see nearby objects comfortably and distinctly without corrective eyeglasses. This condition is called presbyopia (Fig.3.7). This occurs due to diminished flexibility of the ciliary muscles and eye lens. Sometimes, a person may have both myopia and hyperopia. Such people often require bifocal lenses.

### Treatment

Presbyopia is corrected using convex lenses, which can be used for reading and any other work involving looking at nearby objects.

### Xerophthalmia

Xerophthalmia is dryness of the eyes. It is caused by a reduction in tear formation. Vitamin A supplements are given to patients with xerophthalmia.



Astigmatic cornea distorts the focal point of light in front of and/or behind the retina

Fig. 3.6: Astigmatism

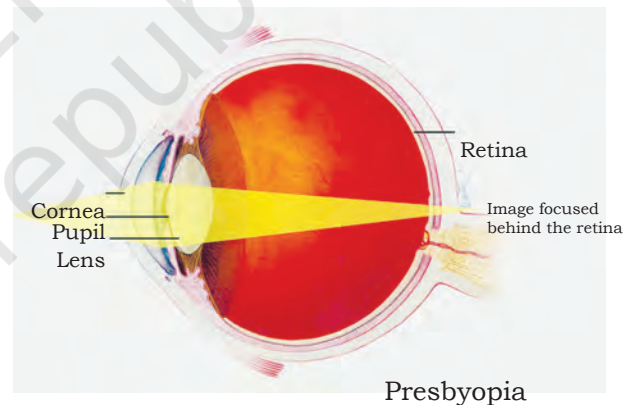


Fig. 3.7: Presbyopia

## Symptoms

These include night blindness, itching and eye irritation. In addition to the eyes being very dry, there is a loss of lustre of the surface of the eye. The cornea becomes soft and gradually opaque.

## Some other eye problems

(i) *Dry eyes*: When the eyes do not have enough tears, it results in dry eyes. It may develop due to working on computers or using mobile phones for a long time. The dry eye syndrome is a condition when the eyes are unable to secrete sufficient amount of tears to keep the eyes lubricated. In this condition, the patient complains of a foggy vision.

(ii) *Watery eyes*: When the eyes handle an excess of tears, it results in watery eyes.

(iii) *Eye pain*: This implies the inconvenience that can happen inside and around the eye. It normalises on its own without treatment.

(iv) *Eye emergencies*: These occur when chemicals or a remote object gets into the eye, or can happen because of an accident that influences the surrounding area of the eye. Emergencies require prompt medical attention.

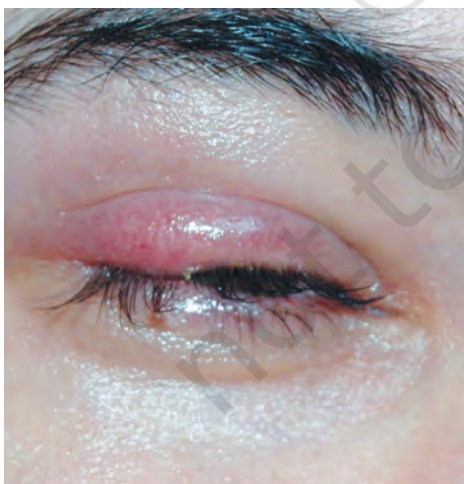

Fig. 3.8: Eyelid Problems

(v) *Excess of tearing*: Excess of tears can take place due to improper light conditions, wind or temperature changes. Securing your eyes by wearing sun or protective glasses can frequently take care of this problem. Sometimes, tearing may additionally imply that you have a more genuine problem. For example, an eye infection or a blockage of the tear duct, allergens.

(vi) *Eyelid problems*: The eyelids secure the eye, disperse tears, and control the amount of light entering the eye (Fig. 3.8). Agony, itching, watering from eye, are some of the symptoms occurring due to eyelid problems, such as hanging eyelids, flickering or aggravated external edges

of the eyelids close to the eyelashes. Eyelid problems frequently might be treated with cleaning, medicines or surgery.

(vii) *Foreign particle in the eye*: Any foreign particle, such as dust, entering the eye can create uneasiness and needs proper attention.

(viii) *Blepharitis*: It is the swelling of the roots of the eyelash. The reason for such a condition is still vague, but allergies, parasites, dandruff, and certain drugs may increase the probability of the condition.

(ix) *Eye redness*: It happens when the blood vessels of the eyes get swollen. It can happen because of dry air, dust or allergies. Uveitis is the inflammation of the uvea—the middle layer of the eye that consists of the iris, ciliary body and choroid. This can be caused by eye injury and inflammatory diseases. Exposure to toxic chemicals, such as pesticides and acids used in the manufacturing processes can also cause uveitis.

### Practical Exercise

Visit your nearest eye clinic with your friends and teacher, and find out what sort of treatment methods they use for various eye infections. Note your observations and include them in your portfolio of activities.

### Check Your Progress

#### A. Fill in the blanks

1. Myopia is a condition when a person can see \_\_\_\_\_ objects clearly, but cannot see \_\_\_\_\_ objects.
2. Dry eyes occur when the eyes do not have enough \_\_\_\_\_.

#### B. Short answer questions

1. What are the causes of diminishing of vision?
2. What is photophobia?
3. Describe presbyopia and its treatment.



### SESSION 3: EYE INJURIES

In this session, you will learn about the causes, general symptoms, precautions and management of eye injuries.

#### Ocular trauma injury

Ocular trauma refers to an injury to the eye, either accidental or intentional. Trauma can occur due to various types of injuries during birth, domestic work and in sports. The most common type is occupational injury which may occur at an agricultural or industrial workplace. Trauma to the lens, or eye damage can be caused by three types of injuries: mechanical, physical and chemical.

#### Mechanical injury

These include blunt injuries (caused by blunt objects, like a ball or a fist) and penetrating injuries (caused by a sharp object, like a knife, compass, etc.). A blunt injury may cause lens opacity, either immediately or after sometime. A perforating injury results in opacity of the eye lens at the site of injury to the lens and progresses to complete opacity. This often requires immediate surgery.

- Blunt injury for example, caused by a fist or ball;
- Perforating injury for example, caused by sharp instruments; and
- Explosive injury for example, caused by a gunshot, bomb blast or firecrackers.

#### Physical injury

The lens is extremely sensitive to ionising radiation—for example, gamma rays, UV rays, etc., especially on long-term exposure to these agents. Physical injury can be caused by thermal, flame, hot liquids, radiation and electrical contact. Exposure to radiation and electric current may produce physical injuries to the lens while acids, alkalis and metals are the causes of chemical injuries. Cataract due to electrical injury may regress, remain stationary or mature to complete cataract over a period of months or years. Microwave radiation does not have much effect on the lens.



## Chemical injury

This can occur due to acid or alkali. Small pieces of metal, especially iron and copper which enter accidentally in the eye, can also cause cataract.

### Precautions

Work-related trauma is preventable and every effort should be made for its prevention. Precautions and adequate safety measures are necessary in high risk areas, like industries, agricultural fields and sports. Some of the preventive measures which can be adopted to prevent injury to eyes are as follows:

- Do not rub the eye.
- Use the corner of a soft clean cloth to draw particles out of the eye, or hold the eyelids open and flush the eyes continuously with clean water. If a particle is large or sticks in the eye, do not attempt to remove it and consult the doctor immediately.
- Cover the eye with a pad and go to an eyecare professional at the earliest. When the chemical agent has entered the eye, flush the eye and surrounding area with clean water for 30 minutes.
- Use a protective glass shield, a helmet and spectacles to prevent accidents.
- Do not neglect any form of eye injuries.

### Management of eye injuries

- Remove the person from the source of the injury to a relatively safe place.
- If the person is unconscious, stabilisation of his general status is a priority over looking for eye injuries.
- The injured person may require investigations, like X-ray and CT scan to identify damage to the bones, soft tissue and eyeball.
- A tear of the eyelid, conjunctiva, cornea needs to be sutured at the earliest.
- Traumatic cataract may need surgery to restore vision, depending on the location and density of the opacity. More serious complications, like



## NOTES

retinal detachment or vitreous haemorrhage may need surgery.

- Foreign bodies lodged inside the eye may also require surgical removal.
- Conditions like sub-conjunctival haemorrhage require only an antibiotic and observation, as they resolve on their own in a matter of weeks.

### Practical Exercise

Visit a vision centre or an eye clinic and study the common eye injuries that the patients come to the centre/clinic for. Write a short note on any two eye injuries that you learned about during your visit.

### Check Your Progress

#### A. Fill in the blanks

1. Ocular trauma refers to any injury to the eye, either \_\_\_\_\_ or intentional.
2. Traumatic lens or eye damage can be caused by three types of injuries: \_\_\_\_\_, physical and chemical.
3. Remove the person from the \_\_\_\_\_ of the injury to a relatively safe place.
4. \_\_\_\_\_ cataract may need surgery to restore vision.

#### B. Short answer questions

1. What is ocular trauma and its causes?
2. Describe the precautions for preventing eye injuries.
3. How to address conditions like sub-conjunctival haemorrhage?

